

REPRINT

BENHA MEDICAL JOURNAL

SPLIT-THICKNESS CALVARIAL CRANIOPLASTY

**Ahmed Diraz MD, D. Sc, Mohamed El-Hadidy MD
and Nasser M. Sayed Ahmed MD**

**Published by
Benha Faculty of Medicine**

*Volume 20 Number 2
May 2003*

SPLIT-THICKNESS CALVARIAL CRANIOPLASTY

**Ahmed Diraz MD, D. Sc, Mohamed El-Hadidy MD
and Nasser M. Sayed Ahmed MD***

Departments of Neurosurgery and Plastic, King Abdulaziz Hospital
and Oncology Center, Jeddah, Saudi Arabia.

*Department of Neurosurgery, King Fahd Hospital,
Al-Madinah Al- Munawarah, Saudi Arabia.

Abstract

Twelve patients underwent split-thickness calvarial bone grafting using high-speed drill and osteotomies for bone harvesting from June 1999 to May 2002 in two neurosurgical departments at King Abdulaziz Hospital and Oncology Center in Jeddah, and King Fahd Hospital in Al-Madinah, Saudi Arabia. These patients were reviewed to show the indications and advantages of the procedure. All patients were studied preoperatively with computed tomographic scans and skull plain X-ray films. The follow-up period ranged from 1 to 22 months. All patients had survived functional bone graft. There were no major intra-operative complications, postoperative infection or remarkable sequelae. In 2 patients intraoperative dural tears occurred and were repaired without any postoperative cerebrospinal fluid leak or sequelae. Results showed that patient's own calvarial bone graft provides an excellent and alternative solutions for skull bone defects with all the immediate and long-term biological advantages that come with using autogenous tissues.

Keywords: Cranioplasty - split-thickness calvarial graft - autogenous bone graft- skull bone defect

Introduction

Cranioplasty is among the oldest surgical procedures. Trauma, infection, tumors, and compression caused by brain edema are some of the reasons for the remov-

al of bone. Cranioplasty is usually performed with autogenous bone, metals, acrylic resin, ceramics, or titanium Baumer et al 1979, Blair et al, 1980, Hayward et al, 1999 and Kobayashi et al, 1981. Autog-

enous bone graft provides the optimal material to be used in reconstruction of the skeleton Springfield et al, 1996. In order to overcome some of the disadvantages of grafts taken from other parts of the body, Psillakis et al, 1979 and Santoni-Rugiu 1969 had used the outer table of the skull bone for repair of skull defects. In this series, we present twelve patients with skull defect who underwent split-thickness calvarial cranioplasty. Detailed clinical data, indications, and advantages of the technique are presented.

Materials and Method

Twelve patients with different causes of skull defect had been treated with split-thickness calvarial graft in two different neurosurgical departments between June 1999 and May 2002. Full data about these cases are illustrated in table 1. There was a male preponderance (75%). Their ages varied from 8 to 44 years (mean 23.4 years). Two patients were children (cases 7 and 8). The majority of skull defects (92%) in these patients were related to direct head trauma as road traffic

accidents (RTA), assaults or falling over sharp objects. In only one patient cranioplasty was done after removal of the involved bone flap invaded by meningioma. In all but one patient there was no definite history of infection before the procedure. In this case the infection was related to post-traumatic brain abscess which was aspirated and treated with antibiotics. Cranioplasty was then done 8 months after complete clinical and radiological resolved of the brain abscess. Skull CT scan and plain X-rays were performed in all patients. The skull defects mainly involved the frontal bone with variable affect of either the parietal or temporal regions of the skull. According to that the cranioplasty was carried out through a bicoronal skin flap with simultaneous exposure of the skull defect and the donor site from which the outer table was harvested (figure 1). The area of the donor graft is split into inner and outer tables with an oscillating saw and thin osteotomes with avoiding the cranial sutures. The outer table is stabilized over the bone shelf at the edge of the recipient site with stainless steel wires or with micro-

plates and screws. The wound is closed in two layers over a drain. The details of this surgical technique were addressed elsewhere. The time of surgical (TOS) intervention after occurrence of skull defect ranged from 4 months to 10 years. Inadvertent intraoperative dural tear occurred in two patients during dural dissection then repair of the dura was done in a water-tight fashion immediately. In one patient with midfrontal skull defect extending down to orbital roof, the frontal air

sinus was entered. Mucosal stripping with obliteration of the nasofrontal duct was performed as the posterior wall was not involved. No remarkable postoperative sequelae were noticed in any patient of this series. All patients - except one - were regularly followed up in the outpatient clinic for 1-22 months postoperatively and showed satisfactory protection of the brain and cosmetic reconstruction. No bone resorption or infection occurred during that time (figure 2).

Table 1- Case Summaries

Case	Sex M/F	Age (Y)	Cause of skull defect	History of infection	Site of skull defect	TOS	Intraoperative complications	Follow-up period	Postoperative complications
1	M	17	Fall from height	-	Midfrontal	4 m	Frontal sinus injury	22 m	-
2	M	37	RTA	-	Left FP	NA	-	14 m	-
3	M	19	RTA	-	Right FT	1 Y	-	18 m	-
4	M	18	RTA	-	Left F	10 Y	Dural tear	1 m	-
5	F	15	RTA	-	Left F	1 Y	-	20 m	-
6	M	44	Meningioma	-	Left F	8 m	-	16 m	-
7	F	10	RTA	-	Right FP	18 m	-	9 m	-
8	M	8	RTA	-	Left F	6 m	-	-	-
9	M	24	Assault	-	Right F	2 Y	Dural tear	6 m	-
10	F	33	Fall from height	-	Left FP	6 m	-	4 m	-
11	M	26	RTA	Yes	Right FP	8 m	-	15 m	-
12	M	30	Assault	-	Midfrontal	6 m	-	13 m	-

Legend:

M: Male NA: Not available m: Month

F: Female FP: Frontoparietal

Y: Year FT: Frontotemporal

RTA: Road Traffic Accident TOS: Time of surgery

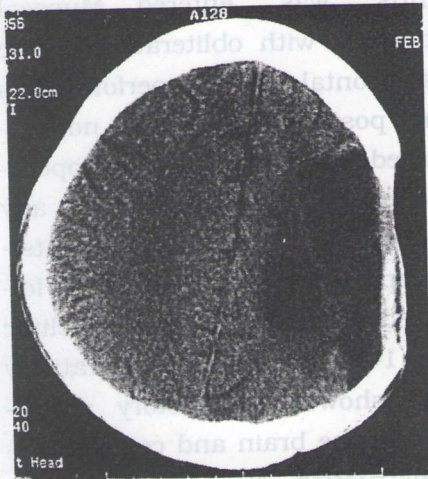


Fig. 1 : Preoperative brain CT.




Fig. 3 : shelf of bony edge at recipient site.

Case	Sex	Age (Y)	Cause of skull defect	History of infection	Site of skull defect	TOS	Intraoperative complications	Follow-up period	Postoperative complications
1	M	27	Fall from height		Midline	4 m	Frontal sinus injury	22 m	
2	M	37	RTA		Left FT				
3	M	19	RTA		Right FT				
4	F	28	RTA		Left F				
5	F	28	RTA		Left F				
6	F	28	RTA		Left F				
7	F	28	RTA		Left F				
8	F	28	RTA		Right FT				
9	F	28	RTA		Left F				
10	F	28	RTA		Right FT				
11	F	28	RTA		Left F				
12	F	28	RTA		Right FT				
13	F	28	RTA		Midline				

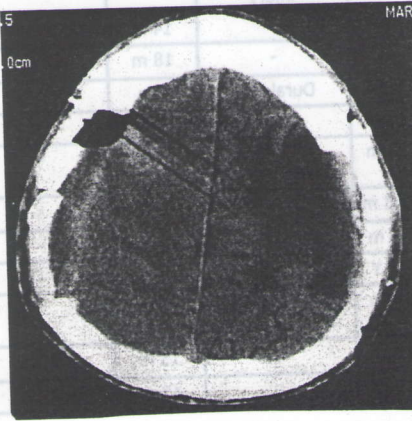


Fig. 2 : Postoperative brain CT.

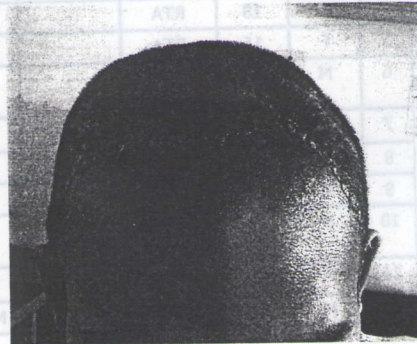


Fig. 4 : post-operative picture of head of the patient.

Discussion

Autogenous bone is the most suitable material for cranioplasty because of its physiological similarity to the skull Santoni, 1969. A patient's own bone can provide an alternative with all the immediate and long-term biological advantages (and resource benefits) that come with using autogenous tissues. Autogenous bone grafts for cranioplasty have been performed with tibia, rib, sternum, scapula, and iliac bone Beumer et al, 1979 and Blair et al, 1980, but they require a separate incision and often provide less than satisfactory cosmetic results Weber et al, 1987. In an experimental study, Zins and Whitaker 1983, demonstrated the increased surviving mass of membranous (calvarial) versus endochondral bone grafts. The split calvarium represents a readily available and reliable source of membranous bone for grafting Hunter et al, 1990. Many surgeons used the outer table calvarial bone grafts as the material of choice for bony reconstruction, Barone and Jimenez 1997, Frodel 1999, Inoue et al, 1995, Kulali and Kayaalp 1991, Papay et al, 1996 and Weber et al,

1987. This procedure offers several advantages : 1) the bone graft, an autogenous material, can be used in previously infected areas; 2) the reconstruction contour is smooth and natural ; 3) there was no morbidity or scarring at donor site ; 4) surgery time is much shorter than with split rib cranioplasty as the donor bone can be harvested through the same operation field. The variable thickness of the calvarial donor site is the major disadvantage of the technique and accounts for inadvertent entry into the intracranial space. This is especially a problem in the infant or young children in whom the bone is thin Cutting et al, 1990. However, in this series, 2 children (8 and 10 years old) underwent outer table cranioplasty without problem. Barone and Jimenez 1997, found that the minimal calvarial bone thickness for successful split-thickness calvarial grafts in children was 7 mm. In this series, most of the skull defects have resulted from head trauma and that may explain the predominance of males over females as the males are more exposed to the trauma. Split calvarial cranioplasty was

mainly indicated in skull defects resulting from trauma or tumor invasion of the skull bone. The procedure can also extend to include cases of skull defects secondary to congenital malformation or infection, Ilankovan and Jackson 1992, Kulali and Kayaalp 1991, Weber et al, 1987. In all patients the skull defect involved the frontal bone with variable extension to either parietal or temporal region of the skull. This has justified indication of the procedure for esthetic consideration. Moreover, there are many theories suggesting that an underlying physiological alteration may occur which may require the correction of the bone defect where many patients improve after surgery, Dujouvny et al, 1997. In 2 patients in this series intraoperative dural tears occurred which were promptly closed during surgery. Both patients were operated 2 and 10 years after the trauma and dural tears occurred during sharp dissection of the dense fibrous tissue around the bone defect. Another intraoperative complication was violation of the anterior wall of the frontal air sinus in a patient with a midfrontal

basal skull defect. However, the sinus was managed in the routine way to isolate it from the cranial cavity. All of our followed-up patients showed good results without bone resorption or infection. This agrees with the work of other surgeons, Barone and Jimenez 1997, Frodel 1999, Kulali and Kayaalp 1991 and Weber et al, 1987. In conclusion, split-thickness calvarial cranioplasty can achieve satisfactory correction of both functional and esthetic problems in patients with minimal - if any-morbidity. It provides long-term stability with only one incision.

References

- Barone C. M. and Jimenez O. F. (1997)** : Split-thickness calvarial grafts in young children. *J Craniofac Surg*, 8:43-47.
- Beumer J. III., Firtell D. M. and Curtis T. A. (1979)** : Current concepts in cranioplasty. *J Prosthet Dent*, 42:67-77.
- Blair G. A. S., Gordon D. S. and Simpson D. A. (1980)** : Cranioplasty in children. *Childs Brain*, 6:82-91.

- Cutting C. B., Mc Carthy J. G. and Knize D. M. (1990)** : Repair and grafting of bone. In Mc Carthy JG (Ed): Plastic surgery. WB Saunders, Philadelphia, pp 583-629.
- Dujovny M., Aviles A., Agner C., Fernandez P. and Charbel F. T. (1997)** : Cranioplasty: cosmetic or therapeutic?. Surg Neurol, 47:238-241.
- Frodel J. L. (1999)** : Calvarial bone graft harvest in children. Otolaryngol Head Neck Surg, 121:78-81.
- Goodrich J. T., Argamaso R. and Hall C. D. (1992)** : Split-thickness bone grafts in complex craniofacial reconstructions. Pediatric Neurosurg, 18:195-201.
- Grotting J. C., Psillakis J. M., Casanova R. and Vasconez L. O. (1986)** : Craniofacial reconstruction after tumor resection using vascularized outer table calvarial bone flaps. Am J Surg, 152 : 438-441.
- Guyuron B., Shafron M. and Columbi B. (1988)** : Management of extensive and difficult cranial defects. J. Neurosurg, 69 : 210-212.
- Hayward R. D. (1999)** : Cranioplasty: Don t forget the patient s own bone is cheaper than titanium. Br J Neurosurg, 13:490-491.
- Hunter O., Baker S. and Sobol S. M. (1990)** : Split calvarial grafts in maxillofacial reconstruction. Otolaryngol Head Neck Surg, 102:345-350.
- Ilnankovan V. and Jackson I. T. (1992)** : Experience in the use of calvarial bone grafts in orbital reconstruction. Br J Oral Maxillofacial Surg, 30:92-96.
- Inoue A., Satoh S., Sekiguchi K., Ibuchi Y., Katoh S., Ota K. and Fujmori S. (1995)** : Cranioplasty with split-thickness calvarial bone. Neurol Med Chir (Tokyo), 35:804-807.
- Kobayashi S., Sugita K. and Matsuo K. (1981)** : Reconstruction of the sellar floor during transsphenoidal operations using alumina ceramic. Surg Neurol, 15:196-197.

Kulali A. and Kayaalp S. (1991) : Single-table autogenous calvarial grafting for cranioplasty. J Craniomaxillofac Surg, 19:208-211.

Lee C., Antonyshyn O. M. and Forrest C. R. (1995) : Cranioplasty: Indications, technique, and early results of autogenous split skull cranial vault reconstruction. J Craniomaxillofac Surg, 23:133-142.

Papay F. A., Zins J. E. and Hahn J. F. (1996) : Split calvarial bone graft in cranio-orbital sphenoid wing reconstruction. J Craniofac Surg, 7:133-139.

Psillakis J. M., Nocchi V. L. B. and Zanini S. A. (1979) : Repair of large defect of frontal bone

with free graft of outer table of parietal bone. Plast Reconstr Surg, 64:827-830.

Santoni-Rugiu P. (1969) : Repair of skull defects by outer table osteoperiosteal free grafts. Plast Reconstr Surg, 43:157-161.

Springfield D. (1996) : Autograft reconstructions. Orthop Clin North Am., 27:483-492.

Weber R. S., Kearns D. B. and Smith R. J. (1987) : Split calvarium cranioplasty. Arch Otolaryngol Head Neck Surg, 113:84-89.

Zins J. and Whitaker L. (1983) : Membranous versus endochondral bone: implications for craniofacial reconstruction. Plast Reconstr Surg, 72:778-781.